



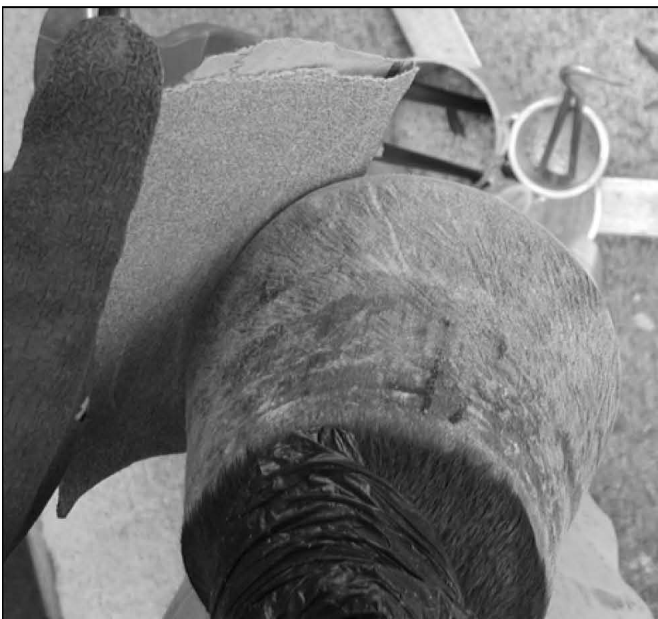**Figure 9a Final Rasping for wall irregularities**  
 [Ref: R/R #2, #3, #5]

This is the final opportunity to harmonize any minor protruding wall irregularities just below the healing zone with the natural thickness of hoof wall. Do this with the file size of rasp, taking care not to scrape the coronary band. Removing periople in the healing zone will not cause harm [See Bulletin #110]. Use long, light sweeping swipes of rasp that begin at top of hoof below the coronary band and end at the turn of the mustang roll.



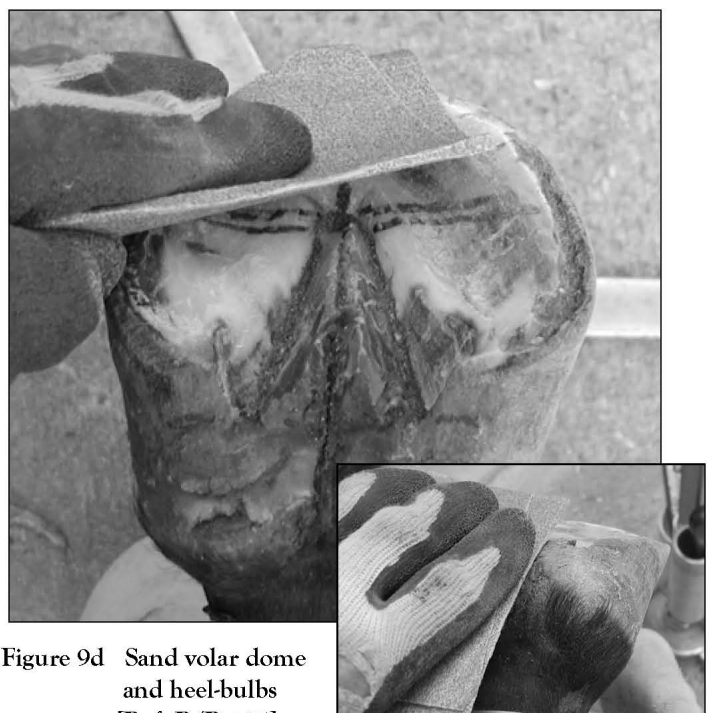
**Figure 9b Sand outer wall to finish**  
 [Ref: R/R #15]

To thoroughly simulate natural wear, we must sand the entire outer wall of capsule. I use a medium grade sand paper to do this. This also gives a striking finish to hoof wall. My clients always appreciated this “fine finish” to my hoof work.



**Figure 9c Sand mustang roll to finish**  
 [Ref: R/R #14, #15]

The mustang roll is also thoroughly sanded. This will help to prevent ravel while endowing the bearing surface of hoof wall with a striking finish.



**Figure 9d Sand volar dome and heel-bulbs**  
 [Ref: R/R #15]

Include the entire bottom of the hoof in the sanding operation as well. This includes the water line, white line, sole, bars, frog, and heel-bulbs—everything below the coronary band.